

Flossing

4TH ISSUE / SEPTEMBER 2024

IFEA WEC 2024
In Glasgow

**CeraSeal
Case
Review**

By Dr. Mostafa Anwar

Upcoming
Events
in Q4

Meta Biomed
Mini Sports day

Explore the World
with Meta Biomed

Meta Biomed
Meeting
in Damascus

**CeraSeal
Clinical Case**
By Dr. Filippo Cardinali

**CERASEAL
IN
SUMMER!**

META BIOMED MEETING IN DAMASCUS




On August 1st and 2nd, the META-BIOMED MEETING IN DAMASCUS 2024 took place at the Sheraton Hotel in Damascus, Syria. Organized in partnership with Nashawy Bros, META-BIOMED's Syrian partner, the event was led by renowned international lecturer Dr. Mostafa Anwar from Egypt. The meeting was further elevated by the support of Dr. Mohammad Osama Al-Jabban, President of Damascus University, and the presence of Prof. Dr. Khaldoun Darwich, Dean of the Faculty of Dentistry.

The conference drew over 600 dental professionals, all gathered to explore the latest in dental technologies and clinical applications, with a particular emphasis on META-BIOMED's innovative product, CeraSeal. Dr. Mostafa Anwar delivered a comprehensive lecture on the effective use of CeraSeal bioceramic sealer in various clinical scenarios. He also showcased recent clinical cases, demonstrating the product's efficacy and versatility in endodontic treatments. The two-day event offered an indepth exploration of CeraSeal's clinical advantages, with the first day dedicated to theoretical discussions and the second day focusing on case studies. Participants were provided with valuable insights on how to integrate CeraSeal into their dental practice successfully.



One of the event's highlights was the interactive Q&A session, where attendees engaged in lively discussions about CeraSeal's application and its benefits. This session offered a platform for knowledge exchange, allowing dentists to share their experiences and enhance their clinical expertise. The META-BIOMED MEETING IN DAMASCUS 2024 not only provided an opportunity to showcase cutting-edge dental technology but also fostered collaboration and knowledge-sharing among dental professionals. Thanks to the dedicated efforts of Nashawy Bros and the esteemed presence of local and international experts, the event concluded with great success, leaving a lasting impact on all participants. 📌



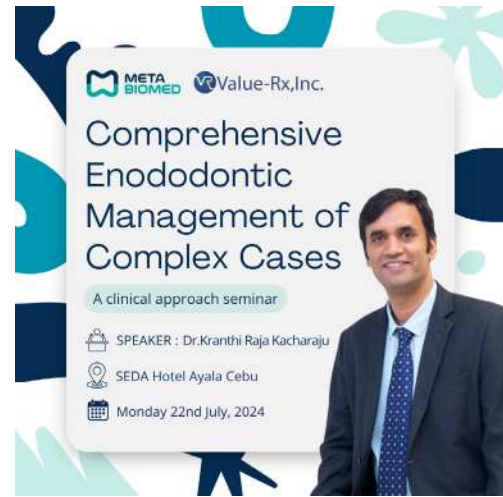
IFEAWEC 2024 IN GLASGOW

Meta Biomed Europe proudly served as a Bronze Sponsor at the International Federation of Endodontic Associations (IFEAWEC) World Endodontic Congress 2024 in Glasgow, Scotland. On September 13, 2024, Meta EU held a successful workshop titled "Warm Vertical Compaction(WVC) and Cold Hydraulic Condensation (CHC) with Bioceramic Sealers," led by Dr. Filippo Cardinali. The session provided hands-on course using CeraSeal, an innovative bioceramic sealer, emphasizing techniques for achieving high-quality obturation. Meta Biomed's participation highlights its commitment to advancing dental care through education and innovation in the endodontic field. 📌


"EXPLORE THE WORLD

One Day Seminar in Cebu

Meta Biomed's Philippine partner, Value Rx, hosted a successful one-day seminar with Prof. Kranthi Raja on July 22 in Cebu. The seminar, focused on the Comprehensive Endodontic Management of Complex Cases, highlighted the effective use of CeraSeal, Meta Biomed's bioceramic sealer. The event included both a lecture and a hands-on session, offering attendees valuable insights and practical experience in endodontic techniques. Meta Biomed looks forward to continued collaboration with our active partners. A special thanks to 'Value Rx' for organizing this outstanding event. 




Endoride in India

ENDORIDE: Exclusive Endodontic Course Successfully Concludes. The ENDORIDE exclusive endodontic course, held from August 2 to 4, successfully concluded under the leadership of renowned doctors Dr. Vishal Gandhi and Dr. Kranthi Raja. This course offered participants the chance to learn and apply the latest endodontic techniques, with a focus on hands-on practice using CeraSeal, Meta Biomed's advanced bioceramic sealer. We extend our heartfelt thanks to all attendees for their tremendous interest and participation in the course. 




IDEX 9th in Egypt

On August 9, Meta Biomed supported partner Alexdent at IDEX 2024 in Egypt. Dr. Mostafa Anwar's sold-out course, "The Art of Advanced BioCeramic Applications," attracted a large audience of dentists with its valuable lectures and hands-on sessions. The strong collaboration between Meta Biomed and Alexdent contributed to the event's remarkable success, with plans to continue offering valuable opportunities for dental professionals in the future. 



WITH META BIOMED"

Live Webinar with CAPP

Meta Biomed is pleased to announce the successful completion of the CAPP Live Webinar titled "How and Why to Use the New Bioceramic Sealers," held on September 9, 2024, at 7 PM (GST). Led by Dr. Claudio, the webinar focused on the clinical benefits of CeraSeal, offering attendees practical tips and detailed instructional videos on its effective use in endodontics. We extend our gratitude to all participants and are committed to providing more valuable educational programs in the future. Stay connected by following Meta Biomed on Facebook and Instagram for upcoming events and updates. 

Supported by  META BIOMED

Organised by 

LIVE WEBINAR

09 SEP
19:00 UAE (GST)
18:00 KSA
17:00 CEST

1 CE CREDIT


Dr Claudio Farnararo, Italy
How and why to use the new bioceramic sealers

General Dentists

www.cappmea.com/webinars

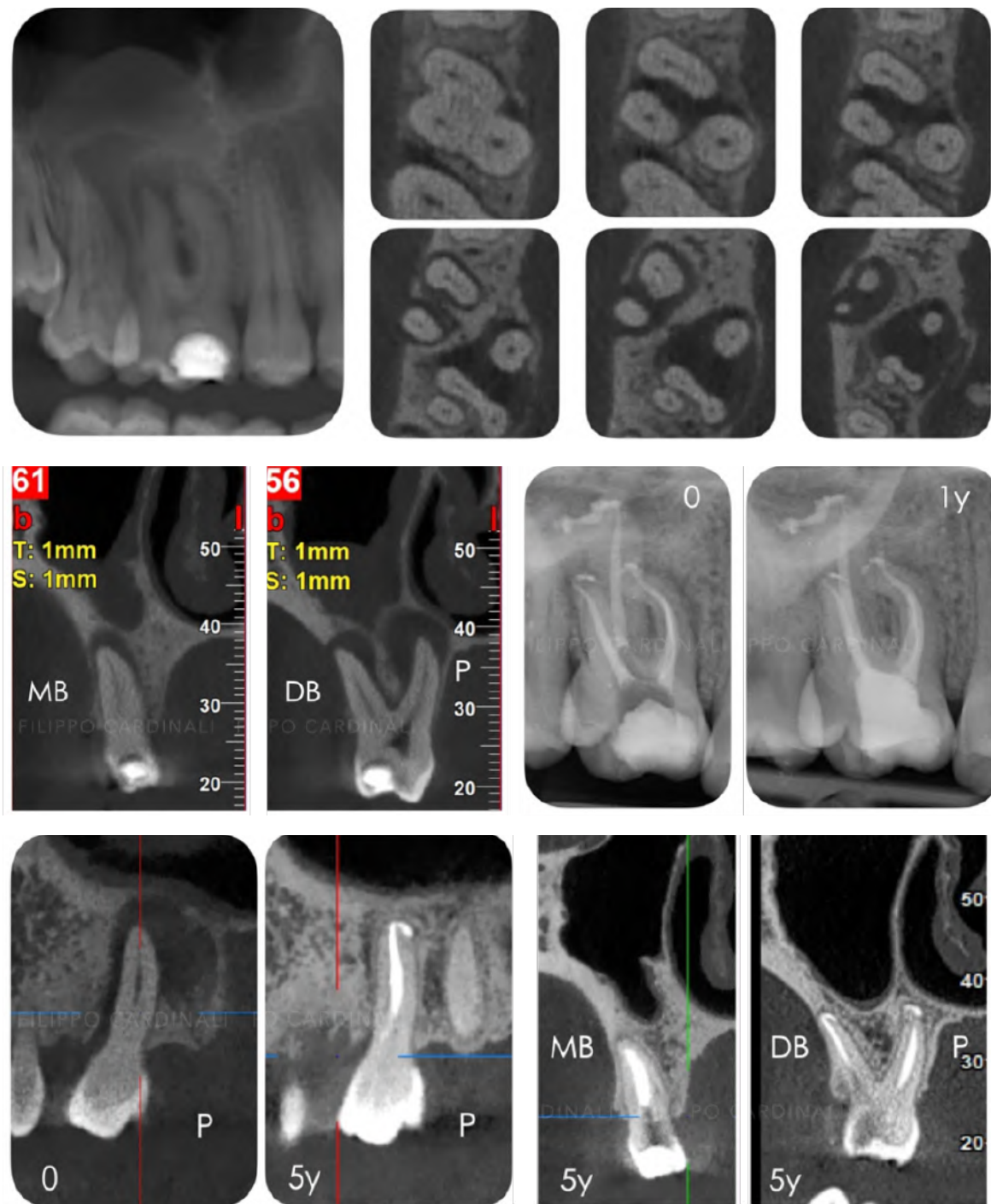
3rd Style Italiano Endodontics International Congress in Greece



From September 27 to 29, Meta Biomed Europe participated as a silver sponsor at the 3rd Style Italiano Endodontics International Congress in Greece. The EU team engaged with attendees at their booth on-site, showcasing products and collaborating with Dr. Filippo Cardinali, whose expertise added great value to the event. Dr. Cardinali delivered a lecture on the bioceramic sealer CeraSeal, followed by a hands-on workshop that received positive feedback. Meta Biomed extends its gratitude to all who visited the booth and looks forward to future events! 

CeraSeal Clinical Case

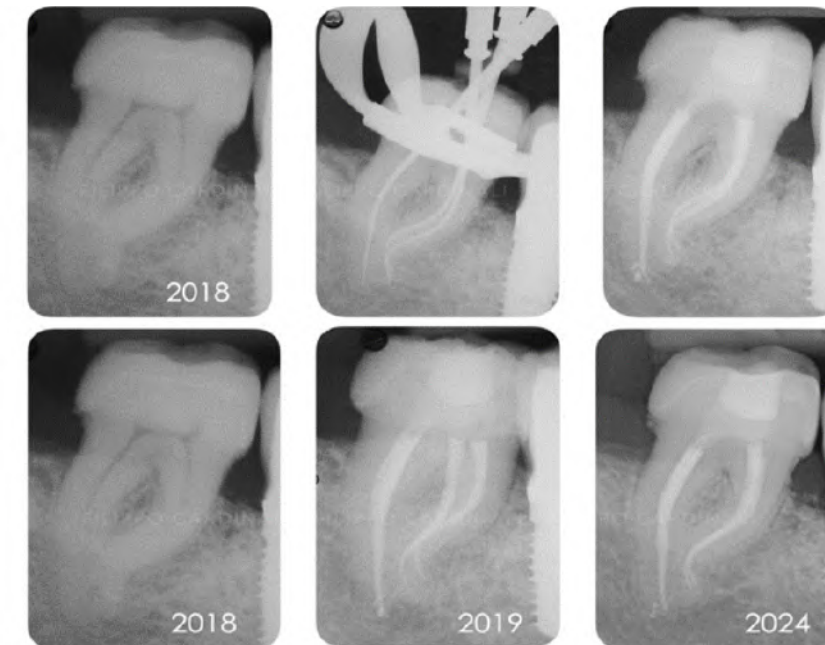Courtesy of Dr. Filippo Cardinali



Treatment of 1.6 with a big periapical lesion - 5 years follow-up. The patient was referred for the treatment of the necrotic 1.6 with a large periapical lesion. The CBCT shows the size of the lesion and mucosal thickening of the Schneiderian membrane of the maxillary sinus. The tooth was symptomatic and was treated in 2 visits. During the first visit the tooth was shaped, cleaned and then dressed with Calcium Hydroxide for 3 weeks. During the second visit the canals were obturated using the Cold Hydraulic Condensation Technique with CeraSeal bioceramic sealer. Review at 1 and 5 years shows the complete healing of the lesion and the physiological mucosal thickening of the Schneiderian membrane of the maxillary sinus. 📧

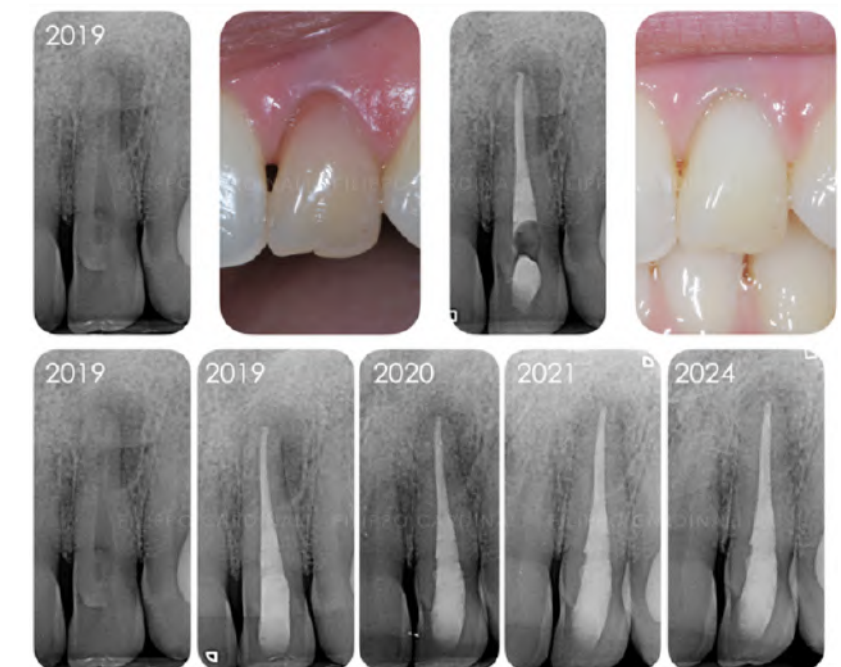
CeraSeal Clinical Case

Courtesy of Dr. Filippo Cardinali



Pulpitis 4.7 with a complex anatomy - 6 years follow-up. Ergonomics is one of the great points related to the bioceramic sealer. This case in the past would have been treated with carrier based obturation technique and an Apical Plug with MTA. After 3 weeks dressing with Calcium Hydroxide, canals were obturated with CeraSeal Bioceramic sealer and Single cone, in the distal canal a barrier was placed to contain the obturation material inside the root canal. Review at 3 and 6 years shows the complete healing of the big lesion. 📧

Retreatment of 2.5 with Deep Probing, and Big distal bone loss - 6 years follow-up. Challenging diagnosis in this case. The patient was referred with a suspect of VRF of 25. Clinical examination reveals the presence of a deep probing with no crack line, the radiographic examination shows a big distal bone loss and an empty area between the fiber post and the obturation material. Obturation using Cold Hydraulic Condensation and CeraSeal bioceramic sealer: a lateral canal that connect the empty canal space and the infection area is present and injected by the bioceramic sealer. The bone loss is a sinus tract inside the gingival sulcus. Review at 1 and 6 years shows the complete healing of the big lesion. 📧



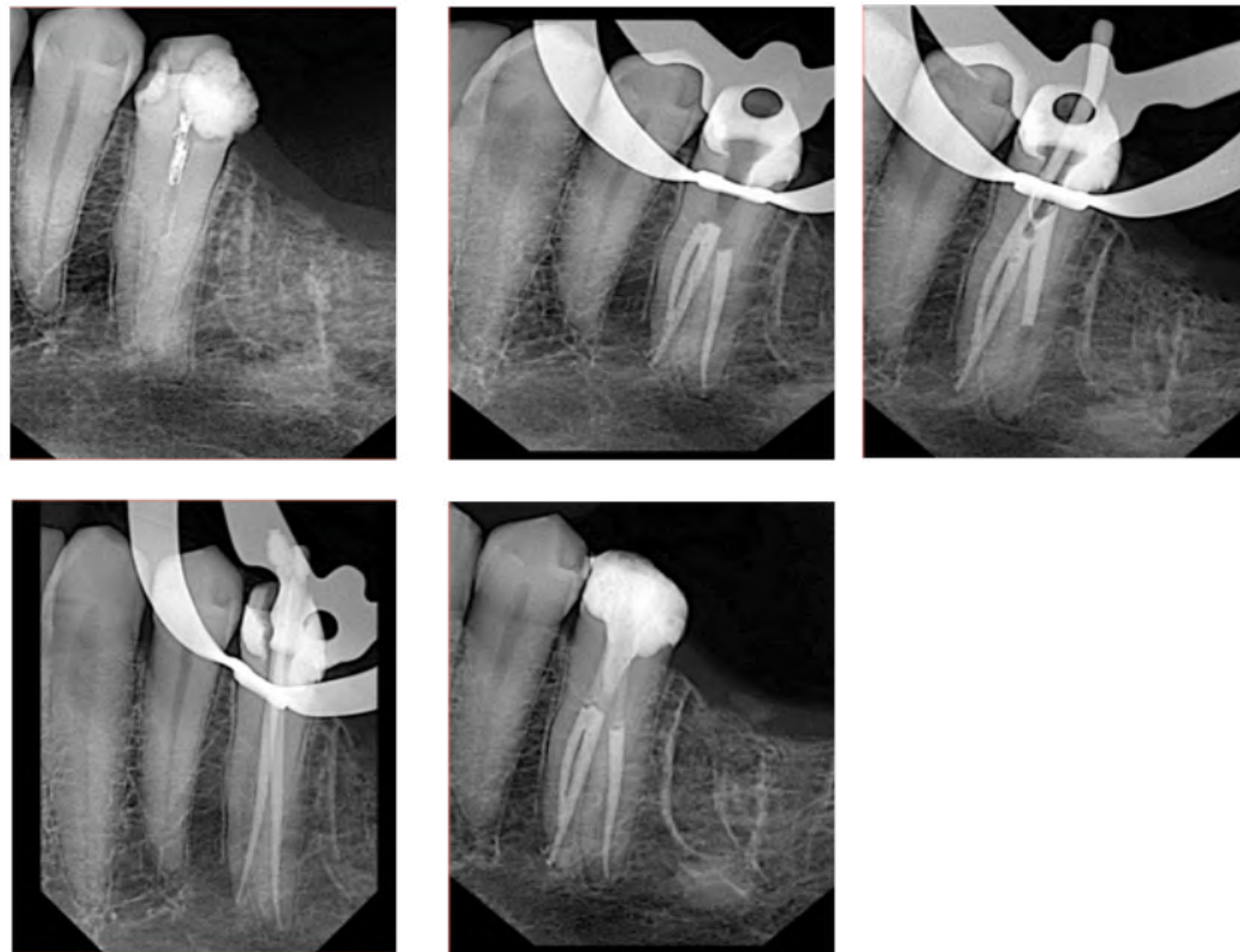
Dr. Filippo Cardinali DDS (Italy)

Graduated summa cum laude in Dentistry in 1992. Active Member and Vice-President of the Italian Society of Endodontics. Certified Member of the European Society of Endodontology. Associate Member American Association of Endodontists. Gold Member of Style italiano Endodontics. Private practice, concentrating mainly in Endodontics and Restorative Dentistry, author of publications on journals of national and international sector, speaker at national and international congresses and workshops.

Instagram @cardinali_endodontics **Facebook** @filippo.cardinali.5

CeraSeal Case Review

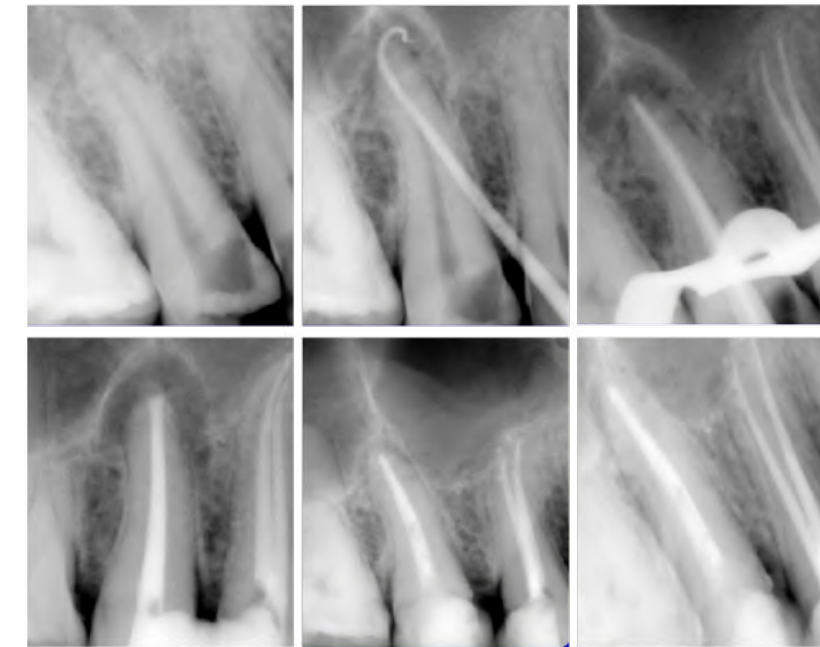
Courtesy of Dr. Mostafa Anwar



Lower left second premolar with three canals. Referred Lower Second Premolar with complex anatomy, after access cavity preparation & Intracanal medication. CBCT shows Two Buccal fused roots with one POE and one lingual root. The complexity lies in RC preparation and obturation, however the obturation can be simplified with the use of CeraSeal Bioceramic Sealer. Application of CeraSeal BC sealer in all the canals, then using a Gutta-percha Single cone in DB canal followed by MB Master cone (Type II Canals). Application of the master cone of lingual canal where "Hot Modified" technique was used to create post space. Note; Lateral Canal in the DB root filled with CeraSeal due to its amazing flowability. 🦷

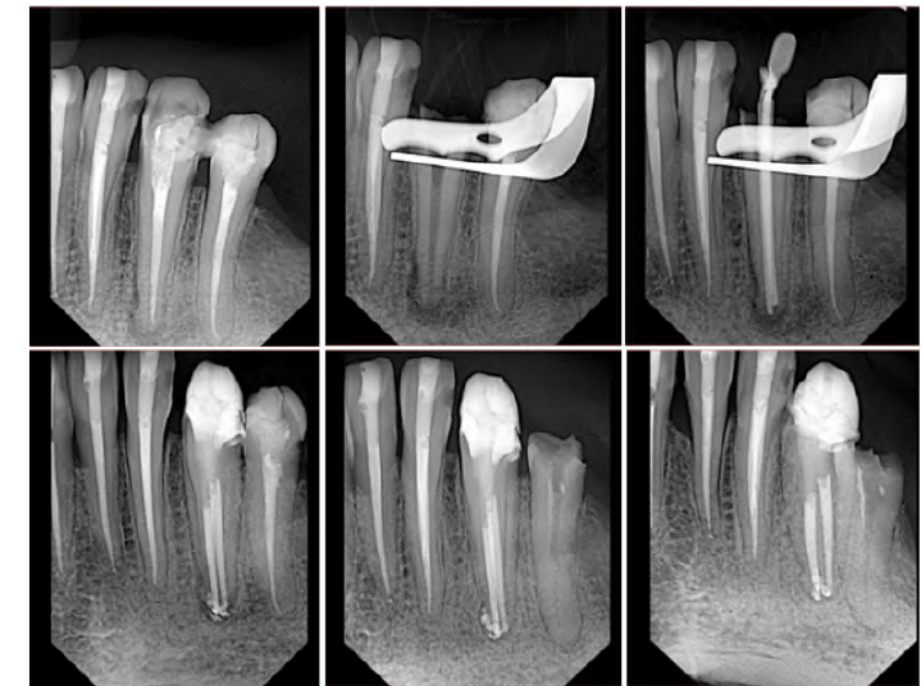
CeraSeal Case Review

Courtesy of Dr. Mostafa Anwar



Upper right second premolar in Single visit. Referred Upper Second Premolar with large periapical lesion and sinus tract confirmed by Gutta percha tracing. Root canal treatment was performed in single visit where dry canals were obtained after mechanical preparation & disinfection protocol, so obturation was done afterwards using Single Gutta percha cone & CeraSeal Bioceramic Sealer. Application of CeraSeal BC sealer in such cases provides many advantages; Antibacterial properties, Allows rapid tissue repair and bone healing over short period of time due to its BioActivity. After One year and Three months, the Follow up Xrays show very nice tissue repair and almost complete healing ensuring a good success rate. 🦷

Retreatment of 2.5 with Deep Probing, and Big distal bone loss - 6 years follow-up. Challenging diagnosis in this case. The patient was referred with a suspect of VRF of 25. Clinical examination reveals the presence of a deep probing with no crack line, the radiographic examination shows a big distal bone loss and an empty area between the fiber post and the obturation material. Obturation using Cold Hydraulic Condensation and CeraSea bioceramic sealer: a lateral canal that connect the empty canal space and the infection area is present and injected by the bioceramic sealer. The bone loss is a sinus tract inside the gingival sulcus. Review at 1 and 6 years shows the complete healing of the big lesion. 🦷



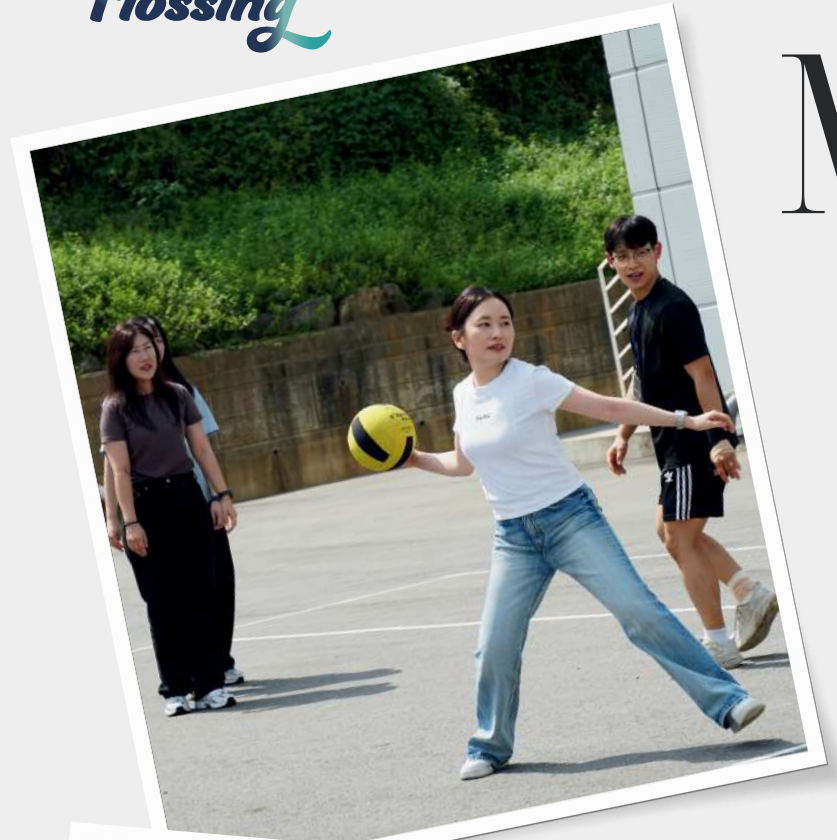Dr. Mostafa Anwar BDS (Egypt)

Graduated from Ain Shams University, Egypt. Diploma of Healthcare & Hospital Management from the American University in Cairo. Master Degree of Endodontics from Ain Shams University on June 2015 & PhD Researcher. International Dental Conferences & Endodontics Key Opinion Leader. Co-Author of Retreatments by SIE. Micro-Endodontics Specialist at private practice, Cairo and the Gulf area.

Instagram @mostafa_anwar Facebook @Mostafa Anwar



Meta Biomed mini sports day



Starting in May, Meta Biomed has been hosting a series of sports events aimed at boosting employee morale and fostering a culture of communication and unity. Under the slogan "One Team, One Dream," eight teams from different departments participated in a friendly competition. The event featured activities such as ball rolling, shoe archery, foot volleyball, and dodgeball, where employees came together, showcasing teamwork and building a strong sense of camaraderie. Teams strategized and competed with enthusiasm, strengthening bonds through fun and collaboration. More than just sports, the event allowed staff to discover new sides of their colleagues, share laughter and support one another, further reinforcing Meta Biomed's unified corporate culture.



META BIOMED

DON'T MISS OUT!

Stay tuned for more updates and get ready for an enriching experience!

UPCOMING EVENTS:

Dr. Filippo Cardinali in Poland	October 5, 2024
Endo Seminar in Temple Univ	October 23, 2023
CAPP Webinar with Dr. Mostafa Anwar	October 30, 2024
Meta Biomed summit Symposium 2024	Coming Soon !

www.meta-biomed.com

Supported by META BIOMED

Organised by CAPP

LIVE WEBINAR

.....

1

CE CREDIT

30 OCT

19:00 UAE (GST)
18:00 KSA
17:00 CEST

Dr Mostafa Anwar, Egypt

3D bioceramic obturation:
Scientific evidence and clinical scenarios

www.cappmea.com/webinars

META BIOMED

META BIOMED SUMMIT SYMPOSIUM 2024

COMING SOON

NOVEMBER, 2024

ADMIT ONE

CODE TICKET 202411

WANTED! New Idea & Clinical Case

We're All Ears for Your Big Ideas!

Share your brilliance with us and help shape FLOSSING by Meta Biomed! Your idea will be the next big thing in our upcoming editions.

Show your BEST Clinical Cases made by CeraSeal

It'd be lovely if we could share your BEST CeraSeal Cases with our tons of followers all around the world. Don't lock up the amazing cases you got in the drawer. Show it off!

For more inquiries: dental@meta-biomed.com

Stay connected with us!

Follow our SNS channels by scanning the QR code and be a part of our engaging conversations and exclusive updates.

SCAN HERE

Flossing is a newsletter made by Meta Biomed (Dental) in 2023, which means taking out various information and delivering it to you, as if you were flossing teeth. [Click to subscribe for Free.](#)

NEW ARRIVAL

CeraPutty

Premixed Bioceramic Putty

Superb
Biocompatibility

Ready-to-use

Fast Setting

Excellent
Healing

Various Uses

- Direct/indirect Pulp capping
- Pulpotomy
- Apexification
- Root-end Filling
- Base/Liner



* CeraPutty 0.5g premixed syringe X 2EA (provided 1g in total)

* Syringe in this photo contains 1g of CeraPutty